

*F-wave Diagnostics, LLC
341 Smith Road
Lake Ronkonkoma, NY 11779
631-455-1562*

Patient: Doe, John
DOB: 11/17/1940
Sex: Male
Ref: Smith, M.D.
Site: # 111

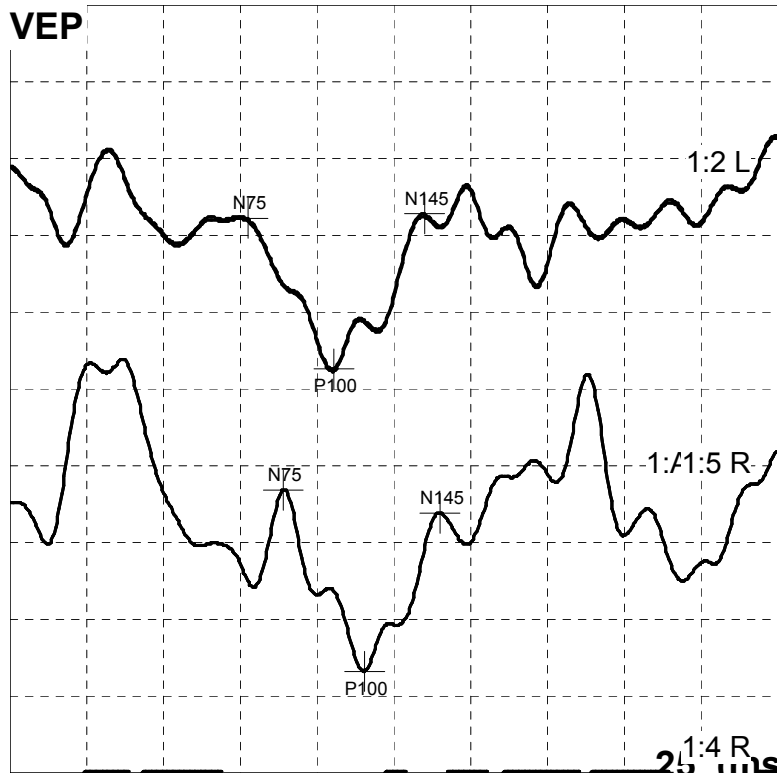
Visual Evoked Potential Report

Visual Evoked Potential (VEP) is a useful electrodiagnostic test for the neurological evaluation of visual signs and symptoms. VEP can accurately indicate lesions in the visual pathway, including the pre-chiasmal path (retina and optic nerve), the optic chiasm and the retrochiasmal portion (optic tract, LGB, optic radiations, and visual cortex).

Monocular full field stimulation produced transient pattern VEP's. Stimulation of one eye produced VEP's that are distributed approximately symmetrically over both occipital areas with a maximum at the midline. They have a major positive peak (P100) preceded and followed by smaller negative peaks. (N75 and N145).

Monocular full field pattern reversal stimulation was performed in each eye using light-emitting diodes mounted in a square matrix. Standard protocol for VEP testing, including electrode placement and recording montages, were followed.

RESULTS: The waveform and numerical data are indicated below:



Trace	N75 (ms)	P100 (ms)	N145 (ms)	N75-P100 (μV)
1:Avg R	89.06	115.23	139.84	7.09
1:1 L	77.34	105.47	134.77	5.85
L-R	11.72	9.77	5.08	1.24

IMPRESSION: The VEP waveform and data was analyzed and compared to the normative data above, Individual subject variables and stimulus characteristics were considered. The impression is as follows:
Normal VEP Study.

Board Certified Neurologist
Electronically Signed
Date:
Time:

Tested By:
Abdel Deraz
Clinical Neurophysiology
Active Member ABRET

Patient: Doe, John

Test Date: 12/13/2013

p. 3